



Contents lists available at ScienceDirect

International Journal of Surgery Case Reports

journal homepage: www.elsevier.com/locate/ijscr

Case report

Pulmonary valve reconstruction by allograft replacement of underdeveloped anterior leaflet in case of late combined pulmonary restenosis after early primary repair

Michael Malyshev^{*}, Alexander Safuanov, Anton Malyshev, Andrey Rostovykh, Dmitry Sinyukov, Natalie Rostovykh

Center of Cardiac Surgery (OOO), Chelyabinsk, Russian Federation

ARTICLE INFO

Keywords:

Pulmonary valve reconstruction
Pulmonary valve restenosis
Congenital heart disease
Allograft
Case report

ABSTRACT

Introduction: The native pulmonary valve (PV) reconstruction is an attractive alternative to a replacement but is challenging due to the systematic underdevelopment of the valve structures in congenital heart diseases. The partial replacement of underdeveloped parts of the valve and saving of well-developed may have advantages versus replacing the whole valve in terms of durability and patient outgrowth of the prosthesis.

Case presentation: This report describes a case of the PV reconstruction by allograft replacement of an underdeveloped anterior leaflet in an adolescent patient who previously corrected pulmonary stenosis during the first year of her life. The normal anatomy of the right and left leaflets was revealed. The rudimental anterior leaflet determined the annular restenosis. The monocusp with the related supporting aortic wall was sewn instead of the anterior leaflet. The Z-score of the pulmonary annulus changed from minus 3, 9 before to +0.8 after the procedure. The excellent function of the PV was observed in 1-year follow-up.

Discussion: Valve deterioration over time will have a less negative impact on the function when it occurs in a limited area. The annular dilatation becomes unlikely if the annulus predominantly consists of natural tissues. The procedural effectiveness allows the transcatheter valve-in-valve therapy in case of late dysfunction. The expected feature of the procedure described is that the growth of the PV remains possible.

Conclusion: If allograft replacement of the PV is scheduled and allograft is available, the partial replacement may be superior to replacement of the whole valve in terms of durability and patient outgrowth of the prosthesis.

1. Introduction

Despite decades of research, the problem of a device for replacing the pulmonary valve has not been ameliorated. Biological substitutions carry a high risk of reoperation [1]. Mechanical prostheses require a strict anticoagulation regime, associated with a lifelong risk of thromboembolic events [2]. The flexible synthetic materials such as expanded polytetrafluoroethylene [1] and polycarbonate urethane [3] have been introduced, but the long-term clinical evaluation is yet to be performed. In light of these shortcomings, native valve reconstructive procedures are of high interest.

This report describes a case of pulmonary valve reconstruction by allograft replacement of only an underdeveloped anterior leaflet in a case of late combined pulmonary restenosis after early primary repair.

2. Case report

The patient was a 12-year-old girl referred by a family physician to our hospital. At admission, she had no complaints and had previously undergone suture closure of an atrial septal defect and pulmonary valve commissurotomy at ten months. There were rough fibrous changes in the cusps and fusions along the lines of coaptation found in the primary operation. At the current presentation, echocardiography showed mild pulmonary insufficiency and a transpulmonary gradient at the rest of 106 mm Hg caused by annular and supra-annular narrowing.

Allograft replacement was planned in the form of a conduit between the right ventricular and pulmonary trunk. The operation was performed via a median sternotomy with cardiopulmonary bypass and blood potassium cardioplegia. The supra-annular stenosis was measured as 8–10 mm with an annular diameter of 12–14 mm that corresponds to

^{*} Corresponding author at: P. O. Box 5977, 454048 Chelyabinsk, Russian Federation.

E-mail address: cardiosur@chel.surnet.ru (M. Malyshev).

<https://doi.org/10.1016/j.ijscr.2021.106410>

Received 11 August 2021; Received in revised form 11 September 2021; Accepted 11 September 2021

Available online 15 September 2021

2210-2612/© 2021 The Authors. Published by Elsevier Ltd on behalf of IJS Publishing Group Ltd. This is an open access article under the CC BY-NC-ND license

(<http://creativecommons.org/licenses/by-nc-nd/4.0/>).

the initial Z-score value minus 3.9.

The transannular incision unexpectedly revealed that the anatomy of the left and right leaflets was preserved. The anterior leaflet had a small length at the annular bracing with the forming of the annular stenosis. The leaflet was changed with the formation of a rough fibrous body (Fig. 1a). A decision was made to replace only the underdeveloped anterior leaflet while creating a tricuspid structure similar to the native valve.

The anterior leaflet was removed, and the transannular incision was limitedly extended within the myocardium of the right ventricle. The noncoronary monocusp with the related supporting aortic wall segment was cut from fresh aortic allograft. It turned out to be proportional to the pulmonary leaflets of the patient (Fig. 1b). The monocusp was sewn in the transannular incision by running a 5/0 polypropylene suture using the allograft wall segment for a partial extension of the supra-annular stenosis along the anterior wall of the pulmonary trunk (Fig. 1c). Two additional xenopericardial patches were used to repair the supra-annular stenosis along the posterior and anterior pulmonary walls.

The final annular size was measured as 22 mm, and the trunk diameter was 24 mm. The postoperative Z-score of the pulmonary annulus was +0.8 (Fig. 2). Transthoracic ultrasound examination showed a pulmonary valve gradient of 12 mm Hg with minimal regurgitant flow. A follow-up was conducted 1 year after the operation with the same echocardiographic findings.

The case has been reported in line with the SCARE 2020 criteria [4].

3. Comment

Pulmonary valve replacement is performed for the primary or late correction of a variety of congenital heart diseases. Allograft and xenograft valves are most commonly used with a high reoperations rate due to structural valve deterioration [1]. The mechanical valve prosthesis was offered to minimize the number of re-operations [5]. However, mechanical prostheses require a strict anticoagulation regime with a life-long risk of thrombosis and bleeding events. It is especially significant in a pulmonary position demanding target values of PT-INR should be kept at the level of 3–3.5 [2]. Both types of prosthesis would carry on a possibility of patient outgrowth of prosthesis if small-sized prosthesis was initially implanted [6].

Expanded polytetrafluoroethylene (ePTFE) [1] and polycarbonate urethanes [3] were introduced recently as a pulmonary valve substitution, but the long-term clinical evaluation is yet to be performed.

A repair of the native pulmonary valve would be the best option, but it is a challenge due to the systematic underdevelopment of the valve structures in congenital heart diseases. These circumstances define a narrow set of conditions in which pulmonary valve repair may be applicable [7].

In this light, the partial replacement of underdeveloped or damaged valve structures with a saving of normal or recoverable ones may be more beneficial in terms of durability versus whole valve replacement. The pulmonary valve reconstructions by partial replacement underdeveloped or damaged single cusp with bovine pericardium [8] or ePTFE [1] were reported on in cases of bacterial endocarditis and late correction of congenital defect correspondently. No reports have been found regarding partial replacement of pulmonary valve structures with allograft tissues, probably due to limited availability and the high cost of such prostheses.

The allograft monocusp implantation in pulmonary position is a known procedure for the primary correction of congenital defects with underdeveloped right ventricular outflow tract [9]. The monocusp is sewn in the pulmonary trunk of small size, giving a dominant part of valve function without restoration of the tricuspid structure. In contrast, in the case described here, the monocusp becomes a part of the tricuspid pulmonary valve structure and provides only one-third of the valve function.

The heterogeneity of biodegradation includes the annular dilatation

with stress fenestrations, fenestration resulting from the weakening of allograft tissue, the loss of flexibility over time, calcification and others. These have a less negative impact if they occur in the singular leaflet than in all structures. Moreover, annular dilatation and related stress fenestrations become unlikely when two-thirds of the annular perimeter is natural tissues.

The presence of two developed leaflets, in this case, suggested that the pulmonary valve be repaired by bicuspidization [7]. However, bicuspidization assumes that there is annular dilatation and sufficient leaflets area and may be used in cases of valve insufficiency rather than stenosis. Also, it has been reported that in contrast to a bicuspid or a quadricuspid structure, the tricuspid valve could produce a larger orifice area and higher contact point, even with different sizes of cusps [10]. The dynamics of pulmonary annulus size and Z-score value in the case supports the effectiveness of tricuspidization (Fig. 2). If dysfunction of the replaced parts of the pulmonary valve will still be developed over time, the transcatheter valve-in-valve therapy might be used because of sufficient pulmonary annulus size.

The expected feature of the procedure described is that the growth of the pulmonary valve remains possible.

The initial condition of the leaflets at the first operation was not seen as having the potential to develop normal anatomy. It was unexpected to see the developed right and left cusps, thus highlighting the importance of careful handling with pulmonary leaflets during any procedure, even those not implying use of the function of the native valve. The saved leaflets may be used for valve repair in the future.

In conclusion, if allograft replacement of the pulmonary valve is planned and fresh or cryopreserved pulmonary or aortic allograft is available, the partial replacement may be superior to replacement of the whole valve in terms of durability and patient outgrowth of the prosthesis. Although the long-term durability has yet to be proven, the results of the 1-year follow-up assessment are encouraging.

Consent

Written informed consent was obtained from the patient and her legal representative for publication of this case report and accompanying images. A copy of the written consent is available for review by the Editor-in-Chief of this journal on request.

Provenance and peer review

Not commissioned, externally peer-reviewed.

Ethical approval

This study is exempt from ethical approval in our institution.

Funding

No source of funding for the publication of this article.

Guarantor

M. Malyshev.

Research registration number

1. Name of the registry: ClinLine platform – clinline.ru
2. Unique Identifying number or registration ID: 01/2021
3. Hyperlink to your specific registration (must be publicly accessible and will be checked) <https://clipline.ru/reestr-klinicheskikh-issledovanij/012021.html>.

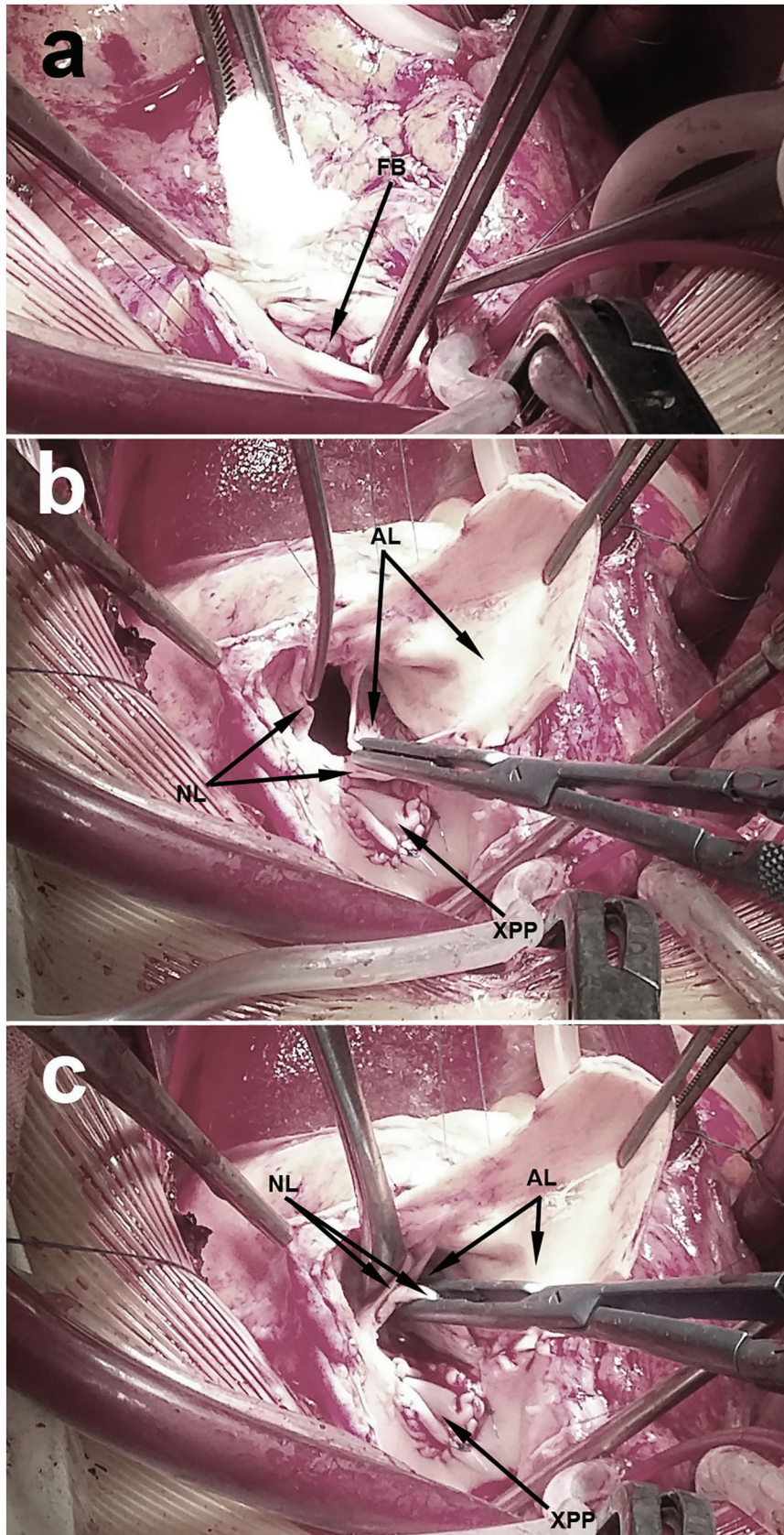


Fig. 1. (a) The stenotic pulmonary valve. FB: the fibrous body on the rudimental anterior leaflet. (b, c) Pulmonary valve views during repair. AL: allograft leaflet with wall segment; NL: the native leaflets; XPP: the xenopericardial posterior patch for supra-annular stenosis repair;

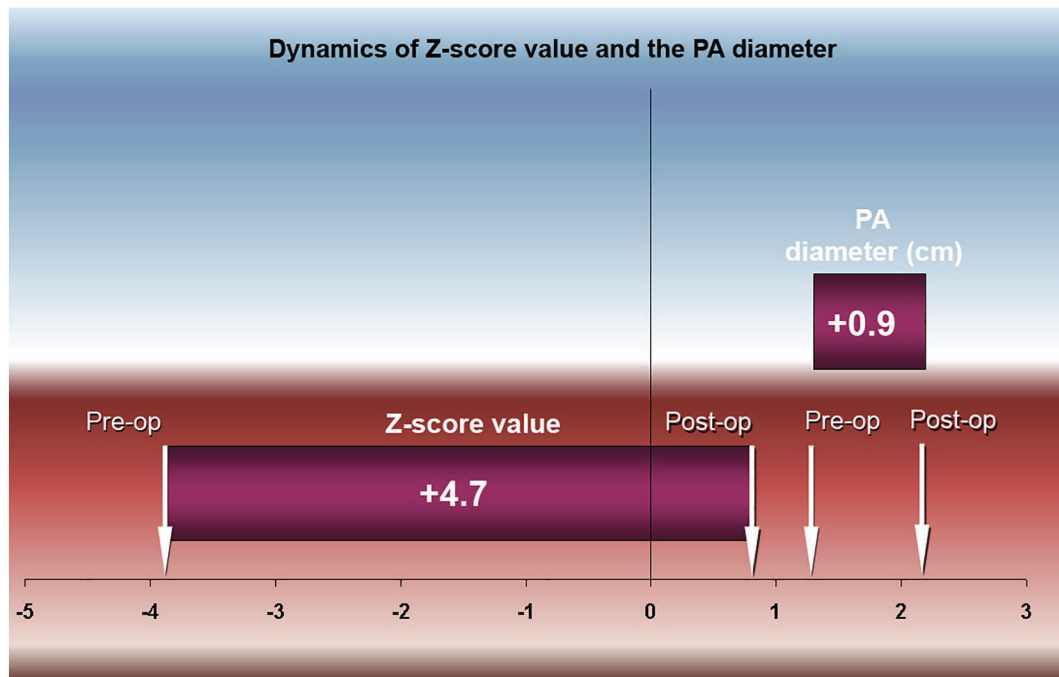


Fig. 2. Dynamics of pulmonary annulus size and Z-score value.

CRedit authorship contribution statement

M. Malyshev: study concept, writer
 Safuanov: interpretation
 Malyshev: data collection
 Rostovykh: data collection
 D. Siniukov: reviewing and editing manuscript
 N. Rostovykh: reviewing and editing manuscript.

Declaration of competing interest

None declared.

References

- [1] C.S. Park, C.H. Lee, Y.O. Lee, G.B. Kim, J.T. Kim, Y.J. Kim, Pulmonary valve repair late after right ventricular outflow tract reconstruction in children and adolescents, *Interact. Cardiovasc. Thorac. Surg.* 10 (2010) 906–909.
- [2] R. Okubo, F. Kimura, H. Harada, D. Kobayashi, T. Shirasaka, H. Kamiya, Simultaneous aortic and pulmonary valve replacement in a young patient after intracardiac repair for tetralogy of fallot: mechanical or biological valve? A case report, *J. Surg. Case Rep.* 5 (2021) 1–3.
- [3] G. Lutter, A. Topal, J.H. Hansen, A. Haneya, J. Santhanathan, S. Freitag-Wolf, D. Frank, T. Puehler, Transcatheter pulmonary valve replacement: a new polycarbonate urethane valve, *Eur. J. Cardiothorac. Surg.* 59 (2021) 1048–1056.
- [4] for the SCARE group, R.A. Agha, T. Franchi, C. Sohrabi, G. Mathew, The SCARE 2020 guideline: updating consensus Surgical Case Report (SCARE) guidelines, *Int. J. Surg.* 84 (2020) 226–230.
- [5] T.W. Waterbolk, E.S. Hoendermis, I.J. den Hamer, T. Ebels, Pulmonary valve replacement with a mechanical prosthesis. promising results of 28 procedures in patients with congenital heart disease, *Eur. J. Cardiothorac. Surg.* 30 (2006) 28–34.
- [6] N. Papadopoulos, A. Esmaeili, A. Zierer, F. Bakhtiary, F. Ozaslan, A. Moritz, Secondary repair of incompetent pulmonary valves, *Ann. Thorac. Surg.* 87 (2009) 1879–1884.
- [7] R.D. Mainwaring, T. Pirolli, R. Punn, F.L. Hanley, Late repair of the native pulmonary valve in patients with pulmonary insufficiency after surgery for tetralogy of fallot, *Ann. Thorac. Surg.* 93 (2012) 677–679.
- [8] T. Glew, M. Feliciano, D. Finkielstein, S. Hecht, D. Hoffman, Case report. pulmonic valve repair in a patient with isolated pulmonic valve endocarditis and sickle cell disease, *Case Rep. Cardiol.* 2015 (2015), 732073.
- [9] D.S. Nath, D.P. Nussbaum, C. Yurko, O.M. Ragab, A.J. Shin, S.R. Kumar, V. A. Starnes, W.J. Wells, Pulmonary homograft monocusp reconstruction of the right ventricular outflow tract: outcomes to the intermediate term, *Ann. Thorac. Surg.* 90 (2010) 42–49.
- [10] K. Ishimaru, T. Kanaya, S. Sakamoto, Y. Sawa, Trileaflet pulmonary valve reconstruction for pulmonary regurgitation in childhood, *Interact. Cardiovasc. Thorac. Surg.* 27 (2018) 914–915.