

*Case
Report*

Surgery for Ascending Aortic Aneurysm and Aortic Valve Insufficiency in Conditions of Active Proceeding Syphilitic Aortitis and Valvulitis

Michael Malyshev, Alexander Safuanov, Anton Malyshev, Andrey Rostovykh,
Dmitry Sinyukov, Natalie Rostovykh, and Vladlena Trushina

A syphilitic aortitis is a late cardiovascular lesion of tertiary syphilis that has become exceptionally rare in the antibiotic era but not eradicated completely. Syphilitic aortitis of ascending aorta complicates in ascending aortic aneurysm formation and aortic valve regurgitation, both requiring surgical treatment. After surgery, lifelong surveillance of the remainder of the aorta is recommended because of a priori supposed high incidence of delayed involvement of noninvolved aortic segments. A 3-year follow-up result of surgery of syphilitic ascending aortic aneurysm with aortic valve regurgitation in condition of active ongoing syphilitic aortitis and valvulitis is described with addressing the dimensions of remaining aortic segments. This case demonstrates that the dilatation of the remainder of the aorta does not occur during 3 years, at least when anti-syphilitic course of antibiotic is used just after operation without additional treatment during the follow-up period. A few reports on surgical treatment of syphilitic aneurysms of the ascending aorta are discussed.

Keywords: syphilitic ascending aortic aneurysm, syphilitic aortic valvulitis, aortic aneurysm, syphilis, tertiary syphilis, cardiovascular syphilis

Introduction

A syphilitic aortitis is a late cardiovascular lesion of tertiary syphilis that has become exceptionally rare in the antibiotic era.¹⁾ However, the disease is not completely eradicated,²⁾ and, currently, occurs more often worldwide.

The activity of a specific inflammation in the aorta results to aneurysm formation in the affected aortic

segment. Aortic valve insufficiency is a common consequence of syphilitic aneurysm of the ascending aorta as a result of concomitant secondary valvulitis and aortic dilatation.³⁾ All lesions are life-threatening and require surgical treatment.

In a recent review, Yuan retrieved publications reporting on syphilitic aortic aneurysm/dissection in English language over last 17 years from several databases (PubMed, Yahoo!, Chinese Medical Current Content) and found only 55 articles. Most of the articles (52) reported on a single case.⁴⁾ Articles reporting on proceeding, ongoing aortitis, and/or valvulitis at the time of performing the operation were not found. The case reports giving follow-up results were also exceptionally rare.

A case of ascending aortic aneurysm combined with aortic valve regurgitation as a result of syphilitic aortitis and valvulitis actively continuing at the time of operation is described herein including a 3-year postsurgical follow-up outcome.

Center of Cardiac Surgery, Chelyabinsk, Russian Federation

Received: December 12, 2022; Accepted: February 15, 2023
Corresponding author: Michael Malyshev. Center of Cardiac Surgery,
454048 Chelyabinsk, P.O. Box 5977, Russian Federation
Email: cardiosur@chel.surnet.ru



This work is licensed under a Creative Commons Attribution-NonCommercial-NoDerivatives International License.

©2023 The Editorial Committee of *Annals of Thoracic and Cardiovascular Surgery*

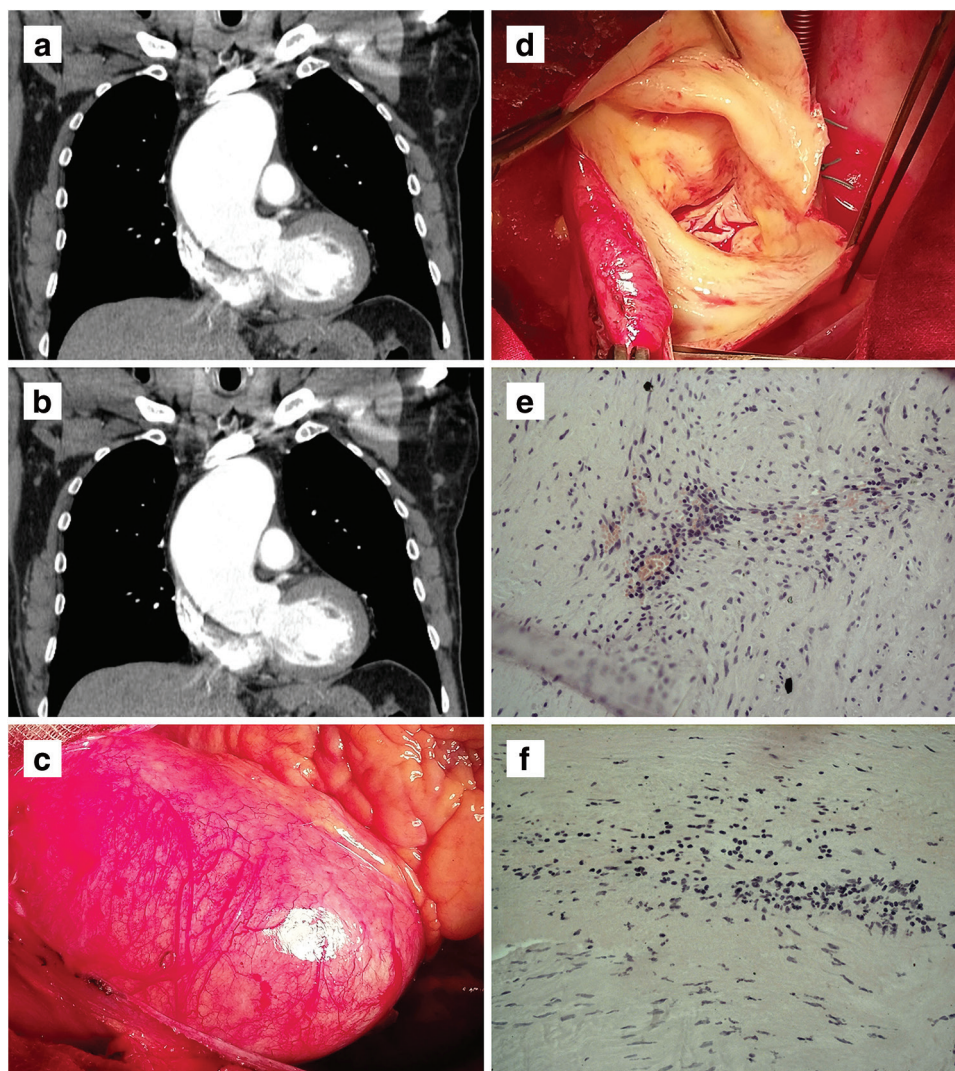


Fig. 1 (a) and (b) Preoperative CT scan (axial and sagittal). (c) Operative view of ascending aorta aneurysm. (d) Operative aortic valve view. (e) Photomicrograph of the aortic adventitial layer with the polymorphic cell infiltration around vasa vasorum (hematoxylin and eosin staining, original magnification $\times 200$). (f) Photomicrograph of the similar polymorphic cells infiltration in the valvular tissue (hematoxylin and eosin staining, original magnification $\times 200$). CT: computed tomography

Case Report

A 54-year-old man was presented with substernal pain and dyspnea during 200 m walking. The diastolic murmur of aortic regurgitation was determined to be not more than grade 3. The arterial pressure was measured as 135/55 mm Hg. The chest contrast-enhanced computed tomography revealed the presence of dilatation of the ascending aorta with a dimension of 7.1 cm and moderate dilatation (in maximum 4.4 cm) of the remainder aorta (**Figs. 1a** and **1b**). The echocardiography demonstrated aortic insufficiency graded as 2 on a 4-grade scale along with moderate thickening of aortic cusps.

The coronarography did not show any coronary lesions. The specific serologic tests, including treponema pallidum hemagglutination assay and fluorescent treponemal antibody-absorption, were sharply positive. All signs of disease coincided with a syphilitic lesion in the active phase, but the patient was unaware of his syphilitic contamination. He did not confirm any signs of early syphilitic stages in his disease history. Laboratory evaluation revealed red and white blood cell counts within normal limits, slight elevation of C-reactive protein 28 mg/L (reference: ≤ 5 mg/L), and erythrocyte sedimentation rate 40 mm (reference: 0–20 mm), with no other changes. The information on the patient is supplied in **Table 1**.

Table 1 Patient characteristics in the template created on the basis of a review of Yuan⁴⁾

Index	Value
Age (years)	53
Sex	Male
Country of patient's origin:	Azerbaijan
The time of cardiovascular syphilis start after the initial infection (years)	Unknown
The type of late cardiovascular syphilitic lesion (coronary ostial stenosis, aortic aneurysm, aortic valve insufficiency, myocarditis)	Ascending aortic aneurysm, aortic valve insufficiency
Aortic aneurysm dimension (cm)	7.1
Shape of aneurysm	Fusiform
Aortic rupture/dissection	No
Aortic valve insufficiency degree	2–3
Comorbidity	No
Symptoms	
Pain (chest, back, chest and back, abdomen, epigastric, flank)	Yes (chest and back)
Dyspnea/shortness of breath	No
Cough	No
Dysphagia	No
Weakness	No
Swelling (leg, face and upper extremity, chest and neck, sternum)	No
Hoarseness	No
Palpitations	Yes
Discomfort (abdominal, laryngeal)	No
Congestive heart failure/deterioration	No
Shock	No
Weight loss	No
Fever	No
Hemoptysis	No
Tamponade	No
Syncope	No
Stroke	No
Sudden death	No
Duration of complaints and symptoms before presentation/admission (months)	10
Clinical signs and associated conditions	
Heart murmur	Yes
Diastolic: aortic valve region, left lower sternal border	
Pericardial effusions	No
Pleural effusions	No
Chest heave/mass/expansile pulsation	
Epigastric pulsation	Yes
Edema, pretibial	No
Waddling gait	No
Tamponade	No
Compression (erosion/perforation) of the adjacent organs	No
Serological confirmation of diagnosis	Yes
Histopathological confirmation of diagnosis	Yes
Co-infection	No
Imaging diagnosis	CT angiography, echocardiography, catheterization
Treatment	Conventional surgery, antibiotic therapy
Length of follow-up (months)	36

CT: computed tomography

The surgical procedure was conventional and performed via median sternotomy with hypothermic (29°C) cardiopulmonary bypass setting via the femoral artery and central bicaval cannulation. The ascending aorta was dilated (**Fig. 1c**) and cross-clamped before the origin of the brachiocephalic artery. Selective intermittent blood cardioplegia was used. The aortic cusps were thickened with slight defective coaptation. The aortic wall and valvular cusps were seen as uniform lesion (**Fig. 1d**). Although the valvular lesion corresponded to the procedure of sparing, the valve was replaced along with the ascending aorta because of fear of getting unacceptable durability of aortic valve in case of its sparing. The 30-mm straight synthetic conduit (Vascutek Ltd., Inchinnan, UK) with 27-mm mechanical bileaflet valve (MEDENG-2, Penza, Russia) was inserted with reimplantation of coronary cuffs (Bentall procedure). Total arch replacement was avoided since the maximal dimension of the aortic arch did not reach the threshold level (≥ 5.0 cm), and syphilitic inflammatory lesion was supposed to be suppressed by anti-syphilitic treatment. The postoperative course was smooth. The patient went home after 10 days. Histopathological examination revealed similar cellular infiltrates in both the aortic and valvular tissues (**Figs. 1e** and **1f**) that matched with the diagnosis of actively proceeding syphilitic aortitis and valvulitis. The patient was referred for specific antibiotic treatment including several stages. The preparatory stage included oral intake of doxycycline 100 mg twice a day for 14 days. Then penicillin 6000000 IU per day intravenously was administered during 28 days. After a 2-week interval, the treatment with penicillin 6000000 IU per day intravenously was repeated for 14 days.

The patient did not receive any additional anti-syphilitic treatment after initially being given just after the operation. He was followed up 3 years after operation with physical examination, renewal of serologic tests, and contrast-enhanced computed tomography. The dynamic measurements of remnant segments of the aorta did not demonstrate any dilatation (**Figs. 2a–2c**).

Discussion

The late syphilitic cardiovascular complications still occur despite significant progress in anti-syphilitic treatment.⁴⁾ In the antibiotic era, the clinical course of syphilis changed and became easier with better prognosis, but the disease was not completely eradicated. In recent decades, the growth of the prevalence of syphilitic cardiovascular complications has even been observed.⁵⁾

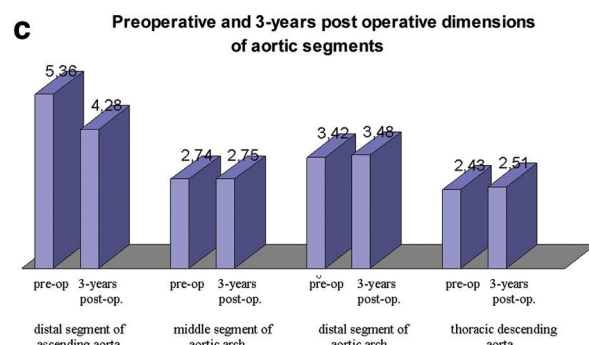
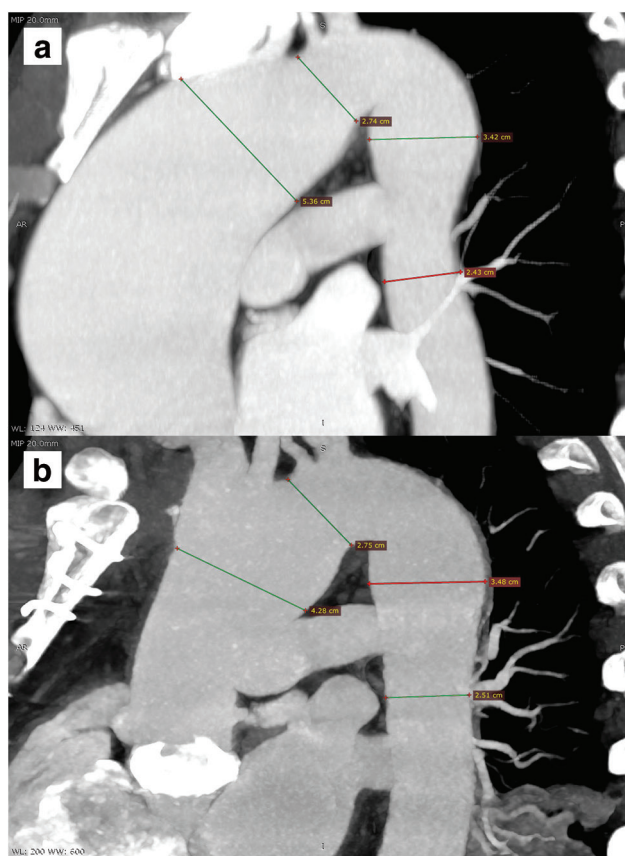


Fig. 2 (a) Preoperative CT (sagittal plane) with marks of dimensions of the distal ascending aorta (5.36 cm), the middle of the aortic arch (2.74 cm), the distal aortic arch (3.42 cm), and the thoracic descending aorta (2.43 cm). (b) Postoperative 3-year follow-up CT (sagittal plane) with the same marks: 4.28 cm, 2.75 cm, 3.48 cm, and 2.51 cm, correspondingly. (c) Preoperative and 3-year follow-up aortic segment dimensions in graphics. CT: computed tomography

During their life, the patients can receive antibiotics for other diseases that mitigate the clinical signs of syphilitic contamination.⁶⁾ The classical stages of syphilis (primary, secondary, and tertiary) overlap with each other or have asymptomatic course. Asymptomatic syphilis can persist in persons who have received suboptimal or no anti-syphilitic treatment.

Cardiovascular complications of tertiary stage include four categories: (1) uncomplicated syphilitic aortitis, (2) syphilitic aortic aneurysm (ascending aorta – 50%, the aortic arch – 10%–15%, the rest – other aortic segments), (3) syphilitic aortic valvulitis with aortic regurgitation (in case of ascending aorta involving), and (4) syphilitic coronary ostial stenosis.^{2,7)} Syphilitic myocarditis presents a separate group of late syphilitic lesions.²⁾

Late syphilitic cardiovascular complications are difficult to be diagnosed since microbial infection is often lacking.⁸⁾ Increasing number of cases and diagnosis difficulties along with effective anti-syphilitic treatment require return syphilis in differential diagnosis of aortic aneurysmal disease.⁵⁾

The case described here showed the clinical debut of the syphilis as the ascending aortic aneurysm with aortic insufficiency, and the anti-syphilitic treatment was never used. The high titers of serologic tests and histopathological data confirmed the proceeding of the syphilitic inflammation at the time of operation. The patient did not confirm any signs of early syphilitic stages in his disease history.

Some questions of surgical management of syphilitic aortitis and its complications remain unclear.

1. Since syphilitic aortitis may be limited not only to the ascending aortic segment, progression of dilatation in the remaining segments is considered as possible.^{5,9)} However, a search for reports on the relapse of syphilitic aortic aneurysms in initially intact segments of the aorta yielded no results.

2. The question is whether the involved aortic valve could be repaired with acceptable durability? The mechanism of syphilitic aortic valve lesion is based on direct inflammatory changes in the aortic cusps. The aortic valvulitis presents as “descending spread” of syphilitic aortitis into the vascularized valve structures restricted to the commissural extremities of the cusps.¹⁰⁾ In contradistinction to rheumatic valvulitis, the syphilitic one does not observe in the body and the free border of the cusps, demonstrating only their fibrous, avascular, and acellular thickening.¹⁰⁾ As a result, the avascular tissue of the aortic cusps is not exposed to rough postinflammatory deformation, presenting only in mild edema and thickening of the aortic cusps. Besides direct morphologic changes of the cusps, aortic valve regurgitation develops due to secondary to ascending aortic annulus/root dilatation. Typically, the degree of regurgitation of both mechanisms does not reach a great level, and the valvular anatomy seems as quite benign, never having been calcified.

Based on the management of the degenerative and rheumatic valve diseases, the authors of some reports of syphilitic aortic aneurysms with aortic regurgitation demonstrate controversial approaches in the management of aortic regurgitation. Some authors have replaced the aortic valve^{11,12)} and others have reported on valve repair.^{6,13)} As a rule, the few reports on valve repair do not contain any information on follow-up outcomes. Grabau et al.⁶⁾ reported on the results of surgical treatment of syphilitic aortic regurgitation in a series of 15 patients. Out of 15 patients, two patients received aortic repair procedures. In both cases, the patients were treated with great doses of penicillin postoperatively. Despite that, the quick progression of aortic regurgitation degree in one case and the endocarditis development in the other were observed. Both patients died in 3 years and 3 months after aortic valve repair, respectively.⁶⁾ The report has substantial limitations in the fact that it was written in the early era of cardiac surgery and unfavorable outcomes of aortic valve repair could be a consequence of other causes.

3. The issue related to above is whether postoperative anti-syphilitic treatment is effective in prevention of aneurysm relapse and providing long-term function of spared valve.

In the case described here, the anatomy of valve lesion corresponded to the procedure of aortic valve repair. The replacement was performed since it is not clear whether valve repair in syphilitic lesion is feasible with acceptable durability, especially when an actively continuing inflammatory process presents. This case demonstrated that dilatation of the remainder of the aorta did not occur during 3 years, at least. The specific antibiotic treatment was used just after the operation and did not renew during follow-up time. Probably, these data may be extrapolated with caution to the durability of valve repair procedures. Since the evaluation of long-term results is strongly essential, further observation of aortic dimensions is required.

Conclusion

The late syphilitic aortitis and valvulitis still occur. Valve lesion demonstrates the anatomy favorable to valve repair procedures, but it is not clear whether the involved aortic valve could be repaired with acceptable durability. The progression of dilatation in the remaining segments of the aorta is not seen for 3 years, at least when the specific antibiotic treatment was used just

Malyshev M, et al.

after the operation, and did not renew during 3 years follow-up.

Informed Consent

Written informed consent was obtained by the patient for publication of this report.

Acknowledgments

The authors express their gratitude to Dr. Anna Kholopova (Regional Bureau of Pathological Anatomy, Chelyabinsk, Russian Federation) for providing a qualified histopathological assessment of the patient's specimen.

Funding Statement

The research did not receive specific funding and was performed as part of the employment of the authors (Center of Cardiac Surgery).

Disclosure Statement

All authors have no conflicts of interest.

References

- 1) Dietrich A, Gauglitz GG, Pfluger TT, et al. Syphilitic aortitis in secondary syphilis. *JAMA Dermatol* 2014; **150**: 790–1.
- 2) Heggtveit HA. Syphilitic aortitis. A clinicopathological autopsy study of 100 cases, 1950-1960. *Circulation* 1964; **29**: 346–55.
- 3) Roberts WC, Ko JM, Vowels TJ. Natural history of syphilitic aortitis. *Am J Cardiol* 2009; **104**: 1578–87.
- 4) Yuan SM. Syphilitic aortic aneurysm. *Z Rheumatol* 2018; **77**: 741–8.
- 5) Girardi LN. Syphilitic aortitis: the bigger picture. *J Thorac Cardiovasc Surg* 2017; **154**: e27–8.
- 6) Grabau W, Emanuel R, Ross D, et al. Syphilitic aortic regurgitation. An appraisal of surgical treatment. *Br J Vener Dis* 1976; **52**: 366–73.
- 7) Madke BS, Agrawal NB, Vaideeswar P, et al. Luetic aortopathy: revisited. *Indian J Sex Transm Dis AIDS* 2010; **31**: 118–21.
- 8) Stansal A, Mirault T, Rossi A, et al. Recurrent tamponade and aortic dissection in syphilis. *Ann Thorac Surg* 2013; **96**: e111–3.
- 9) Žvirblytė R, Ereminienė E, Montvilaitė A, et al. Syphilitic coronary artery ostial stenosis resulting in acute myocardial infarction. *Medicina* 2017; **53**: 211–6.
- 10) Richter AB. Treponema Pallidum in syphilitic aortic valvulitis of a congenitally bicuspid valve with sub-aortic stenosis. *Am J Pathol* 1936; **12**: 129–40.1.
- 11) Kobayashi T, Yagi T, Murakami M, et al. Staged surgical repair for extensive cardiovascular damage by syphilis. *Ann Thorac Surg* 2011; **92**: 1503–6.
- 12) Adhyapak SM, Haridas AK, Yeriswamy MC, et al. Syphilitic aortitis: an uncommon cause of acquired aortopulmonary fistula. *Ann Thorac Surg* 2009; **88**: 1672–4.
- 13) Kawai Y, Nakao M, Niitsu H, et al. Valve-sparing root replacement for syphilitic aortic arch aneurysm with aortic regurgitation. *Jpn J CardioVasc Surg* 2015; **44**: 271–4. (in Japanese)